VIRAL ARTHRITIS

Slide study set #1

Prepared by:

Dr. J. O. OLSON

West Virginia University

Morgantown, West Virginia

Revised by:

Dr. GEORGE E. ONET

Central Veterinary Diagnostic Laboratory

Richmond, Virginia

This slide study set was created in 1972 and revised in 1994; some information may be outdated.

Visit www.aaap.info/slides To Purchase DEMO Copyright by AAAP

COPYRIGHT 1973, 1994

AMERICAN ASSOCIATION OF AVIAN PATHOLOGISTS, INC.

AAAP BUSINESS OFFICE
NEW BOLTON CENTER
382 WEST STREET RD.
KENNETT SQUARE, PA 19348

CD version produced in 2001 with the assistance of the AAAP Continuing Education and Electronic Information Committees

Etiology. Viral arthritis is caused by an RNA nonenveloped virus with icosahedral symmetry and double capsid structure and is a member of the genus reovirus. The viral particle is approximately 75 nm in diameter. Like other reoviruses, this virus is resistant to heat (it withstands 60° C for 8-10 hours) and to pH 3.

Reoviruses can be readily differentiated from other viruses by their typical physicochemical characteristics and the presence of a group specific antigen, demonstrable with the agar gel precipitin test. Cultivation is possible in embryonated chicken eggs, primary chicken cell cultures, and some established cell lines.

The pathogenicity of selected reovirus isolates may be enhanced by coinfection with Eimeria tenella or Eimeria maxima. Also, exposure to infectious bursal disease or particular dietary regimens may increase the severity of viral arthritis clinical signs. Reoviruses may exacerbate disease conditions caused by other pathogens, including chicken anemia agent, *E. coli*, and Newcastle disease virus.

Epizootiology. Reoviruses have been isolated from a variety of clinically diseased avian species: chickens, turkeys, pigeons, ducks, geese, and psittacines. However, a firm etiological relationship was not always established.

Reoviruses spread rapidly; in a period of about one week the whole flock may become infected. The disease seems to have a cyclical nature, in which parental immunity probably plays a part. The clinical stage may run its course in a single outbreak or in some cases continue for several months.

Chickens are most susceptible to pathogenic reoviruses at 1 day of age and then develop an age-related resistance beginning as early as 2 weeks of age.

Transmission of the infection can be horizontal or vertical. Because of virus resistance to inactivation, mechanical means may be an important factor in spreading the infection. The ability of the virus to spread laterally varies from strain to strain and is based primarily on the fact that it is excreted from both the intestinal and respiratory tracts of infected birds. The virus may persist for long periods of time in the cecal lymphoid points and patches. Carrier birds are potential sources of infection for penmates. Vertical transmission plays a major epidemiological role.

DEMO
To Purchase
Visit www.aaap.info/slides
Copyright by AAAP

Clinical signs. The incubation period differs, depending upon virus pathotype, age of host, and route of infection. The incubation period in 2-week-old birds is 1-10 days. Often infections are inapparent and demonstrable only by serology or virus isolation. Many reoviruses cause microscopic inflammatory lesions in the digital flexor and metatarsal extensor tendons, without development of macroscopic lesions. Usually, outbreaks of viral arthritis occur when birds are 4-5 weeks of age. The disease is rare in older birds but has been described in birds 47 weeks of age.

In acute infections, chickens appear stunted and exhibit different degrees of lameness, depending on the severity of morphologic changes. Swelling of the tendon sheaths of the digital flexor tendons of the shank and of the metatarsal extensor tendons above the hock can be detected by gross inspection or palpation. Affected birds tend to sit on their hocks and are reluctant to move. Swelling of the footpad is less frequent. Rupture of the gastrocnemius tendon can occur occasionally and results in the bird's inability to hold the hock joint in an upright position and may lead to ankylosis and immobility. The typical uneven gait in bilateral rupture of the tendon results from the bird's inability to immobilize the metatarsus. A secondary consequence of tendon rupture is rupture of blood vessels. However, in spite of the marked tendon involvement, many birds appear in good condition. Erythrocyte, hematocrit, and total leukocyte determinations are frequently within normal range. In some cases, there is a rise of heterophil percentage and a decrease of lymphocyte percentage.

Morphopathologic changes. Macroscopic lesions in chickens naturally infected with viral arthritis consist of swelling of the digital flexor and metatarsal extensor tendons. The latter lesion can be observed just above the hock and may be readily observed when feathers are removed. The hock joint usually contains a small amount of straw-colored or blood-tinged exudate. In some cases, there is a considerable amount of purulent exudate resembling that seen with infectious synovitis. Early in the infection there is marked edema of the tarsal and metatarsal tendon sheaths. Petechial hemorrhages are frequent in the synovial membranes above the hock.

Internal organs are usually normal.

DEMO
To Purchase
Visit www.aaap.info/slides
Copyright by AAAP

In chronic evolving cases, the inflammatory process leads to hardening and fusion of the tendon sheaths. Small-pitted erosions develop in the articular cartilage of the distal tibiotarsus. They enlarge, coalesce, and extend into underlying bone. Overgrowth of fibrocartilaginous pannus can develop on the articular surface. Condyles and epicondyles are frequently involved.

Histopathologically, edema, coagulative necrosis, heterophil accumulation, and perivascular infiltration can be seen. There are also hypertrophy and hyperplasia of the synovial cells, with infiltration by lymphocytes and macrophages, and proliferation of reticular cells. The latter lesions cause parietal and visceral layers of tendon sheaths to become markedly thickened. The synovial cavity is filled with heterophils, macrophages, and sloughed synovial cells.

In chronic cases, the synovial membrane develops villous processes and lymphoid nodules. An increased amount of fibrous connective tissue and pronounced infiltration or proliferation of reticular cells, lymphocytes and plasma cells develops, appearing as chronic fibrosis of tendon sheaths, with fibrous tissues invading the tendons. Sometimes, tendons are completely replaced by irregular granulation tissue and large villi form on the synovial membrane. Development of sesamoid bones in the affected limb is inhibited. Linear growth of cartilage cells in the proximal tarsometatarsal bone becomes narrow and irregular. Osteoblasts become active and lay down a thickened layer of bone beneath the erosion. Osteoblastic activity is present in the condyles, epicondyles, and accessory tibia, producing osteogenesis and subsequent exostosis. There are transverse and vertical clefts in the femur growth plate, with necrosis of cartilage and fragmentation of the bone, but arthritis is not present.

<u>Immunity</u>. Contact with reoviruses results in specific antibody production, which can be detected by agar gel immunodiffusion, serum neutralization, or chicken embryo assays. Neutralizing antibodies are detectable 7-10 days following infection and precipitating antibodies after approximately 2 weeks. The former seem to persist longer than the latter (over 300 days). The importance of antibodies in establishing protection is not clearly understood, since birds may become persistently infected in the presence of

DEMO
To Purchase
Visit www.aaap.info/slides
Copyright by AAAP

high levels of circulating antibodies. It seems, however, that a certain degree of protection from maternal antibodies in 1-day-old chickens is present.

Diagnosis. Diagnosis is based on correlation between epidemiology, clinical signs, gross pathologic changes, and laboratory testing. Involvement of primarily the metatarsal extensor and digital flexor tendons is the first criterion of suspicion. Histology assists in differentiating between bacterial and mycoplasmal synovitis. Demonstration of reovirus in the tendon sheaths by fluorescent antibody techniques or virus isolation in chicken embryos or chicken embryo liver cells provides further evidence. In 5- to 7-day-old chicken embryos, yolk sac inoculation results in death of the embryos within 3-5 days, with skin and visceral hemorrhagic lesions.

In cell cultures, reoviruses induce cytopathic effects expressed by formation of syncytia and empty spaces in the cell monolayer.

To test virus pathogenicity, inoculation into the footpad of susceptible day-old chickens can be used. If pathogenic, the virus will induce pronounced local inflammation within 72 hours.

Reovirus group-specific antibodies can be readily detected with the agar gel precipitin test (AGP) or indirect fluorescent antibody assay (IFA). The AGP test can be used to identify isolates as reovirus if known positive antiserum is available, or it can be used as an indication of the presence of antibodies in diseased birds. The test is specific for the known reoviruses isolated from chickens but would not distinguish between different serotypes.

Virus neutralization, based on plaque reduction in chicken embryo kidney or chicken embryo liver cell cultures, has been used routinely for determining serotype differences with rabbit or chicken antiserum.

ELISA systems now available from commercial sources are apparently suitable for assessing reovirus antibody levels on a flock basis.

Differential diagnosis. The differential diagnosis should first rule out arthritis caused by *Staphylococcus* or *Mycoplasma synoviae*, but also traumatic arthritis. This can be done mainly by thorough laboratory examinations.

DEMO
To Purchase
Visit www.aaap.info/slides
Copyright by AAAP

Prognosis. The prognosis is usually reserved due to the serious tendo-synovial damages involved and the lack of an effective treatment.

Control and Prevention. Elimination of virus exposure is certainly a difficult task, due to the ubiquitous nature of avian reoviruses, their inherent stability, and the high density confinement-rearing practices in use. Thorough cleaning of poultry houses appears to prevent infection with pathogenic virus in subsequent flocks following removal of an infected flock from the premises. Lye and 0.5% organic iodine solutions are thought to be effective inactivating agents.

To monitor the flocks for viral arthritis using AGP testing, examination of 1 percent of the flock at intervals of 30 days should be sufficient.

Active immunization can be achieved by vaccination with attenuated reovirus, applied by the subcutaneous route. Reovirus vaccination of breeding stock can be done with viable or inactivated vaccines or with combinations of both. The advantages of this type of immunization program include immediate protection of 1-day-old progeny provided by maternal antibodies and a limitation of the potential transovarial transmission.

DEMO
To Purchase
Visit www.aaap.info/slides
Copyright by AAAP

VIRAL ARTHRITIS SLIDE SET

N. O. OLSON
West Virginia University
MORGANTOWN, WEST VIRGINIA
G. E. ONET
Central Veterinary Diagnostic Laboratory
RICHMOND, VIRGINIA

Visit www.aaap.info/slides To Purchase DEMO Copyright by AAAP

SLIDE 1. Chickens with clinical signs of viral arthritis "tendonitis"/"tenosynovitis" tend to sit and are reluctant to move. When they do, many walk with a stilted gait resulting from restricted tendon movement. Wing balancing. (2-4 contributed by Dr. Van der Heide, Dept. of Pathobiology, Univ. of Connecticut, Storrs)
See slides 2, 3, and 4 for other clinical signs.

SLIDE 2. When chickens with clinical signs of viral arthritis "tendonitis"/"tenosynovitis" walk, many do it with a stilted gait resulting from restricted tendon movement. Wing balancing. (contributed by Dr. Van der Heide, Dept. of Pathobiology, Univ. of Connecticut, Storrs)
See slides 1, 3, and 4 for other clinical signs.

SLIDE 3. Many chickens with clinical signs of viral arthritis "tendonitis"/"tenosynovitis" walk with a stilted gait resulting from restricted tendon movement. (contributed by Dr. Van der Heide, Dept. of Pathobiology, Univ. of Connecticut, Storrs)
See slides 1, 2, and 4 for other clinical signs.

SLIDE 4. Chickens with clinical signs of viral arthritis "tendonitis"/"tenosynovitis" tend to wing balance when walking or standing. (contributed by Dr. Van der Heide, Dept. of Pathobiology, Univ. of Connecticut, Storrs)
See slides 1, 2, and 3 for other clinical signs.

SLIDE 5. The tendon sheaths of the shank and above the hock are markedly swollen. (4 contributed by Dr. Van der Heide, Dept. of Pathobiology, Univ. of Connecticut, Storrs)
See also slide 6.

SLIDE 6. The tendon sheaths of the shank and above the hock are markedly swollen. (4 contributed by Dr. Van der Heide, Dept. of Pathobiology, Univ. of Connecticut, Storrs) See also slide 5.

SLIDE 7. A cut section of the digital flexor tendons showing the marked edema of the tendon sheaths and areas between the tendons.

SLIDE 8. Ruptured gastrocnemius tendon followed by hemorrhage is seen in approximately 5% of the affected birds. Gross swelling of the tendon sheaths may or may not be noted. See also slide 9.

SLIDE 9. Ruptured gastrocnemius tendon followed by hemorrhage is seen in approximately 5% of the affected birds. Gross swelling of the tendon sheaths may or may not be noted. See also slide 8.

SLIDE 10. The light brown, blood tinged fluid seen in the sagittal section of the tarsal joint is typical of the joint fluid seen in viral arthritis. This fluid is seen most frequently in the tarsal and femorotibial joints.

SLIDE 11. Smears of the joint fluid (synovia) stained with May-Grunwald-Giemsa stain reveal many heterophils, lymphocytes, monocytes, and macrophages. Normal synovia may contain an occasional monocyte or a sloughed synovial cell. Care should be taken not to squash the cells when making the smear, to prevent the appearance of bizarre cells that are difficult to identify. Blood should be avoided in taking the smear. Heterophils are not seen in normal synovium.

SLIDE 12. Tarsal bursitis may or may not be associated with viral arthritis. Tarsal bursitis occurs in nearly 100% of battery-reared birds in the absence of viral arthritis. The upper leg shows tarsal bursitis plus enlarged digital flexor tendons. The lower leg shows

DEMO
To Purchase
Visit www.aaap.info/slides
Copyright by AAAP

enlarged digital flexor tendons with no tarsal bursitis. Breast blisters have been associated more with management conditions than with viral arthritis, as has tarsal bursitis.

SLIDE 13. Starting at about 42 days post-infection, erosions appear in the cartilage of the posterior and distal tibia.

SLIDE 14. Normal tendon sheaths from the digital flexor tendons of the shank (H & E X 30)

SLIDE 15. Infected tendon sheaths from the digital flexor tendons of the shank of a chicken with viral arthritis (6 weeks of age, 3 weeks post-inoculation), showing a thickened synovium due to hyperplasia of synovial cells and connective tissue with extensive accumulation of lymphocytes, plasma cells, and heterophils. The accumulation of these cell types is present in the synovial cavity (H & E X 30). (Contributed by Dr. K. M. Kerr, Department of Pathology, Ohio state University, Columbus). Chickens at this stage may recover or progress to the chronic stage, as seen in 21
See also slides 16, 17, and 18.

SLIDE 16. Infected tendon sheaths from the digital flexor tendons of the shank of a chicken with viral arthritis (6 weeks of age, 3 weeks post-inoculation), showing a thickened synovium due to hyperplasia of synovial cells and connective tissue with extensive accumulation of lymphocytes, plasma cells, and heterophils. The accumulation of these cell types is present in the synovial cavity (H & E X 30). (Contributed by Dr. K. M. Kerr, Department of Pathology, Ohio state University, Columbus). Chickens at this stage may recover or progress to the chronic stage, as seen in 21.
See also slides 15, 17, and 18.

SLIDE 17. Infected tendon sheaths from the digital flexor tendons of the shank of a chicken with viral arthritis (6 weeks of age, 3 weeks post-inoculation), showing a thickened synovium due to hyperplasia of synovial cells and connective tissue with

DEMO
To Purchase
Visit www.aaap.info/slides
Copyright by AAAP

extensive accumulation of lymphocytes, plasma cells, and heterophils. The accumulation of these cell types is present in the synovial cavity (H & E X 30). (Contributed by Dr. K. M. Kerr, Department of Pathology, Ohio state University, Columbus). Chickens at this stage may recover or progress to the chronic stage, as seen in 21.
See also slides 15, 16, and 18.

SLIDE 18. Infected tendon sheaths from the digital flexor tendons of the shank of a chicken with viral arthritis (6 weeks of age, 3 weeks post-inoculation), showing a thickened synovium due to hyperplasia of synovial cells and connective tissue with extensive accumulation of lymphocytes, plasma cells, and heterophils. The accumulation of these cell types is present in the synovial cavity (H & E X 30). (Contributed by Dr. K. M. Kerr, Department of Pathology, Ohio state University, Columbus). Chickens at this stage may recover or progress to the chronic stage, as seen in 21.
See also slides 15, 16, and 17.

SLIDE 19. Chronic viral arthritis with fibrosis in the digital flexor tendon.

SLIDE 20. Pannus formation in viral arthritis. (Contributed by Dr. Van Der Heide, Dept. of Pathobiology, Univ. of Connecticut, Storrs).

SLIDE 21. Taken from same area as 13, showing chronic changes in the synovium and development of fibrous tissue and lymphoid follicles composed of proliferating lymphocytes (H & E X 30)

SLIDE 22. Fluorescent antibody staining of the synovium, demonstrating the virus in the synovial cells 3 weeks post-inoculation (x 400).

SLIDE 23. The virus particles are arranged in a crystalline array (V) in the cytoplasm of a mesenchymal cell (4 days after inoculation of chorioallantoic membrane) of a chicken embryo with viral arthritis WVU 2937 (x 50,000). (Contributed by Elizabeth Walker, Dept. of Anatomy, West Virginia University Medical School).

DEMO
To Purchase
Visit www.aaap.info/slides
Copyright by AAAP

SLIDE 24. Inoculation of 10-day-old embryonating chicken eggs on the dropped chorioallantoic membrane (CAM) results in the development of whitish plaques in 3 to 5 days post-inoculation. From a 16-day-old embryo, 6 days post-inoculation.

SLIDE 25. Whitish plaques on the dropped chorioallantoic membrane (CAM) from a 16-day-old embryo, 6 days post-inoculation.

SLIDE 26. Inoculation of 5- to 7-day-old embryonating chicken eggs by the yolk sac route or on the dropped CAM results in death of the embryo in 3-5 days. This markedly hemorrhagic 12-day-old embryo died 5 days post-inoculation via the yolk sac route.

SLIDE 27. Embryos inoculated with lower concentrations of the virus survive until the 16th to 20th day. The embryo shown here is 17 days old, 10 days post-inoculation via the yolk sac route. One section of the liver is cut away to reveal the spleen. The embryo is slightly dwarfed. The heart, liver, and spleen are enlarged and contain necrotic foci.

SLIDE 28. Growth of the virus on cell culture: the most striking effect is the formation of syncytia by the epithelial cells in chick kidney culture, often as early as 18-24 hours post-infection. (Contributed by Dr. Stanley Kleven, University of Georgia, Athens).
See also slides 29 and 30.

SLIDE 29. Growth of the virus on cell culture: The syncytia degenerate and float free, leaving holes in the monolayers. (Contributed by Dr. Stanley Kleven, University of Georgia, Athens).
See also slides 28 and 30.

SLIDE 30. Growth of the virus on cell culture: Syncytia are not formed in cultures of fibroblasts, but the cells round up and degenerate 72 hours post-infection (phase contrast X 50). (Contributed by Dr. Stanley Kleven, University of Georgia, Athens).
See also slides 28 and 29.

DEMO
To Purchase
Visit www.aaap.info/slides
Copyright by AAAP

SLIDE 31. The agar gel precipitin (AGP) test is a rapid method used for the diagnosis of viral arthritis. The center well contains virus prepared from ground CAM. The top and bottom wells contain positive serum. The other 4 wells contain negative serum and normal ground CAM. Note white precipitin line between the positive serums and virus. The AGP test is used to detect antibodies to reoviruses. For specific serotype identification of the virus, neutralization or complement fixation test should be used.

DEMO
To Purchase
Visit www.aaap.info/slides
Copyright by AAAP

REFERENCES

1. Dalton P. J., Henry R,. 1967, Tenosynovitis in poultry, Vet. Rec., 80, 638

2. Guneratne J. R. M., Jones R. C., Giorgiou K., 1982, Some observations on isolation and cultivation of avian reoviruses, Avian. Pathol., 11, 453-462

3. Ide P. R., 1982, Avian reovirus antibody assay by indirect immuno-fluorescence using plastic microculture plates, Can. J. Med. 46, 39-42

4. Jones R. C., Georgiou K., 1966, Reovirus-induced tenosynovitis in chicken: The influence of age at infection, Avian Pathol., 13, 441-457

5. Olson N. O., Kerr K. M., 1966, Some characteristics of an avian arthritis viral agent, Avian Dis., 10, 470-476

6. Olson N. O., Solomon D. P., 1968, A natural outbreak of synovitis caused by a viral arthritis agent, Avian Dis., 12, 311-316

7. Onet E., 1983, Artrita virala, In: viruses and Viral Diseases of Animals, Vol. II, Ed. Dacia, Cluj-Napoca, 339-341

8. Page R. K., Fletcher O. J., Rowland G. N., Gaudry D., Villegas P., 1982, Malabsorption syndrome in chickens, Avian Dis., 26, 618-624

9. Page R. K., Fletcher O. J., Villegas P., 1982, Infectious tenosynovitis in young turkeys, Avian Dis., 26,924-927

10. Robertson M. D., Wilcox G. E., 1986, Avian Reovirus, Vet. Bull, 56, 155-174

11. Rosenberger J. K., Olson N. O., 1991, Reovirus infectious, in: Diseases of Poultry, Ninth Edition, Iowa State University Press, 639-647

12. Stuart B. P., Cole R. J., Waller E. R., Vesonder R. F., 1986, Proventricular hyperplasia (malabsorption syndrome) in broiler chickens, J. Environ. Pathol. Toxicol. Oncol., 6, 369-385

13. Van Der Heide L., 1977, Viral arthritis/tenosynovitis: A review, Avian Pathol., 6, 271-284

14. Van Der Heide L., 1983, Development of an attenuated pathogenic reovirus vaccine against viral arthritis, Avian Dis., 27, 698-706

15. Wood G. V. V., Nicholas R. A. J., Herbert C. N., Thornton D. H., 1980, serological comparisons of avian reoviruses, J. Comp. Path 90, 29-38

DEMO Visit www.aaap.info/slides To Purchase Copyright by AAAP

1.01.jpg

1.02.jpg

1.03.jpg

1.04.jpg

1.05.jpg

1.06.jpg

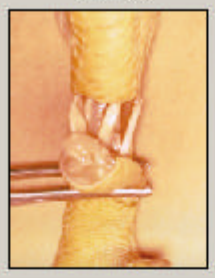
1.07.jpg

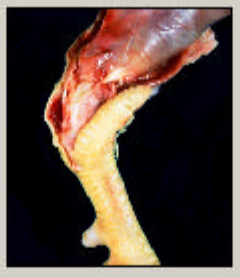
1.08.jpg

1.09.jpg

1.10.jpg

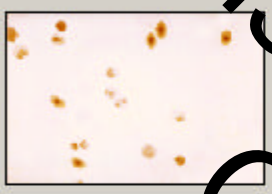
1.11.jpg

1.12.jpg

1.13.jpg

1.14.jpg

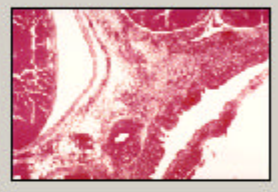
1.15.jpg

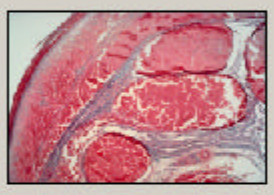
1.16.jpg

1.17.jpg

1.18.jpg

1.19.jpg

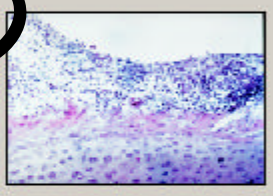
1.20.jpg

1.21.jpg

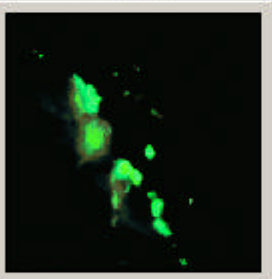
1.22.jpg

1.23.jpg


1.24.jpg

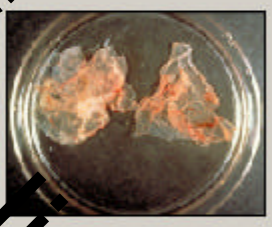
1.25.jpg

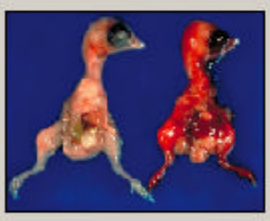
1.26.jpg

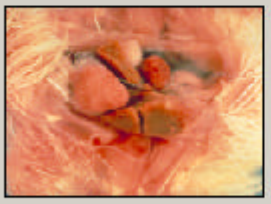
1.27.jpg

1.28.jpg

1.29.jpg

1.30.jpg

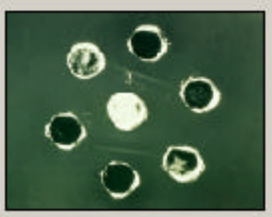
1.31.jpg

DEMO
To Purchase
Visit www.aaap.info/slides
Copyright by AAAP

SLIDE 1. Chickens with clinical signs of viral arthritis "tendonitis"/"tenosynovitis" tend to sit and are reluctant to move.
See slides 2, 3, and 4 for other clinical signs.

Click here to access (101.jpg) jpg file for printing and copying

DEMO
To Purchase
Visit www.aaap.info/slides
Copyright by AAAP

SLIDE 2. When chickens with clinical signs of viral arthritis "tendonitis" "tenosynovitis" walk, many do it with a stilted gait resulting from restricted tendon movement. Wing balancing. (contributed by Dr. Van der Heide, Dept. of Pathobiology, Univ. of Connecticut, Storrs)
See slides 1, 3, and 4 for other clinical signs.

Click here to access (1.02.jpg) jpg file for printing and copying

DEMO
To Purchase
Visit www.aaap.info/slides
Copyright by AAAP

SLIDE 3. Many chickens with clinical signs of viral arthritis "tendonitis" "tenosynovitis" walk with a stilted gait resulting from restricted tendon movement. (contributed by Dr. Van der Heide, Dept. of Pathobiology, Univ. of Connecticut, Storrs)
See slides 1, 2, and 4 for other clinical signs.

Click here to access (1.03.jpg) jpg file for printing and copying

DEMO
To Purchase
Visit www.aapinfoslides
Copyright by AAAP

SLIDE 4. Chickens with clinical signs of viral arthritis "tendonitis"/"tenosynovitis" tend to wing balance when walking or standing. (contributed by Dr. Van der Heide, Dept. of Pathobiology, Univ. of Connecticut, Storrs)
See slides 1, 2, and 3 for other clinical signs.

Click here to access (1.04.jpg) jpg file for printing and copying

DEMO
To Purchase
Visit www.aaap.info/slides
Copyright by AAAP

SLIDE 5 The tendon sheaths of the shank and above the hock are markedly swollen.

Click here to access (1.05.jpg) jpg file for printing and copying

DEMO
To purchase
Visit www.aaap.info/slides
Copyright by AAAP

SLIDE 6. The tendon sheaths of the shank and above the hock are markedly swollen.

Click here to access (1.06 mb) jpg file for printing and copying

DEMO
To Purchase
Visit www.aaap.info/slides
Copyright by AAAP

DEMO
To Purchase
Visit www.aaap.info/slides
Copyright by AAAP

SLIDE 7. A cut section of the digital flexor tendons showing the marked edema of the tendon sheaths and areas between the tendons.

Click here to access (1.07.jpg) jpg file for printing and copying

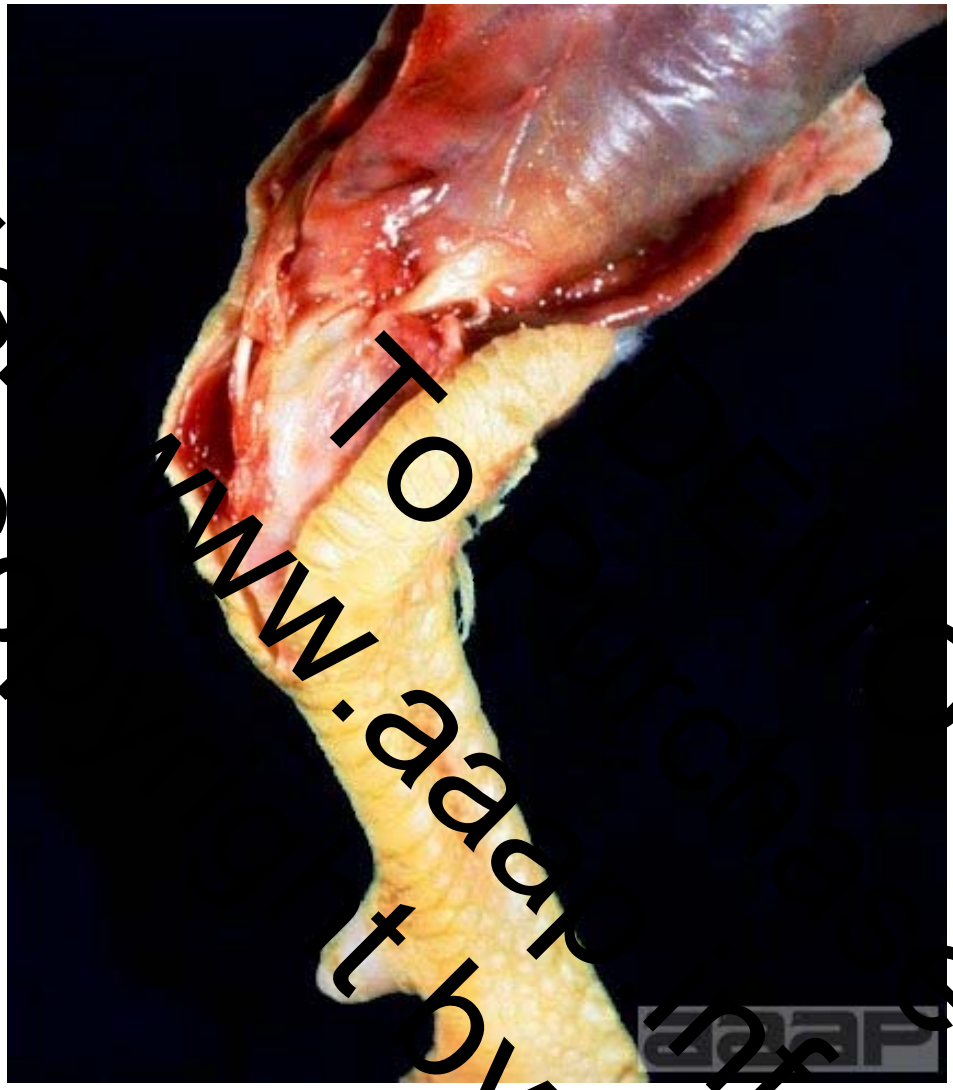

SLIDE 8. Ruptured gastrocnemius tendon followed by hemorrhage is seen in approximately 5% of the affected birds. Gross swelling of the tendon sheaths may or may not be noted. See also slide 9.

Click here to access (1.08.jpg) jpg file for printing and copying

Visit www.aaap.info/slides
Copyright © 2010 AAAP
To

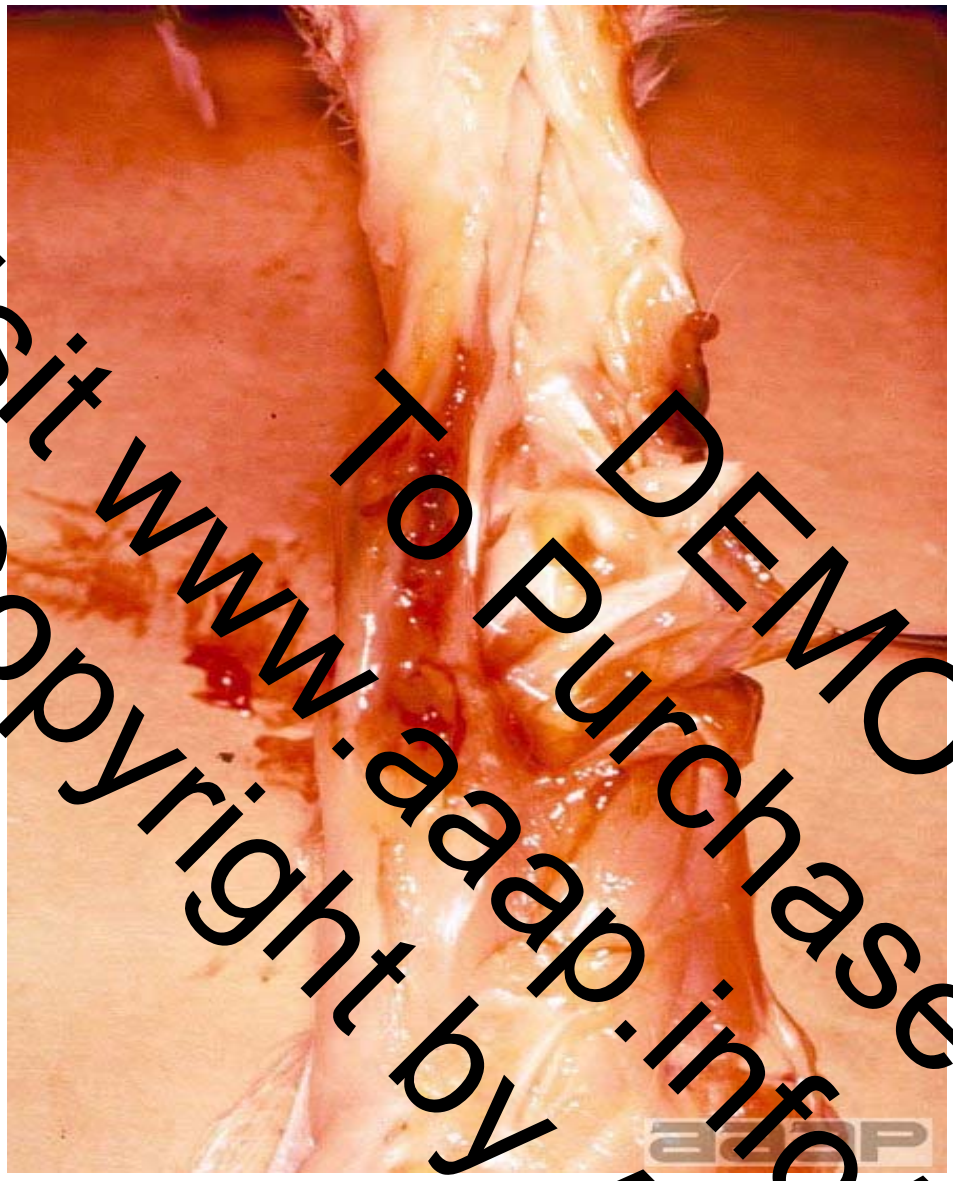

SLIDE 9. Ruptured gastrocnemius tendon followed by hemorrhage is seen in approximately 5% of the affected birds. Gross swelling of the tendon sheaths may or may not be noted. See also slide 8.

Click here to access (1.09.jpg) jpg file for printing and copying

DEMO
To Purchase
Visit www.aaap.info/slides
Copyright by AAAP

SLIDE 10. The light brown, blood tinged fluid seen in the sagittal section of the tarsal joint is typical of the joint fluid seen in viral arthritis. This fluid is seen most frequently in the tarsal and femorotibial joints.

Click here to access (1.10.jpg) jpg file for printing and copying

DEMO
To Purchase
Visit www.aaap.info/slides
Copyright by AAAP

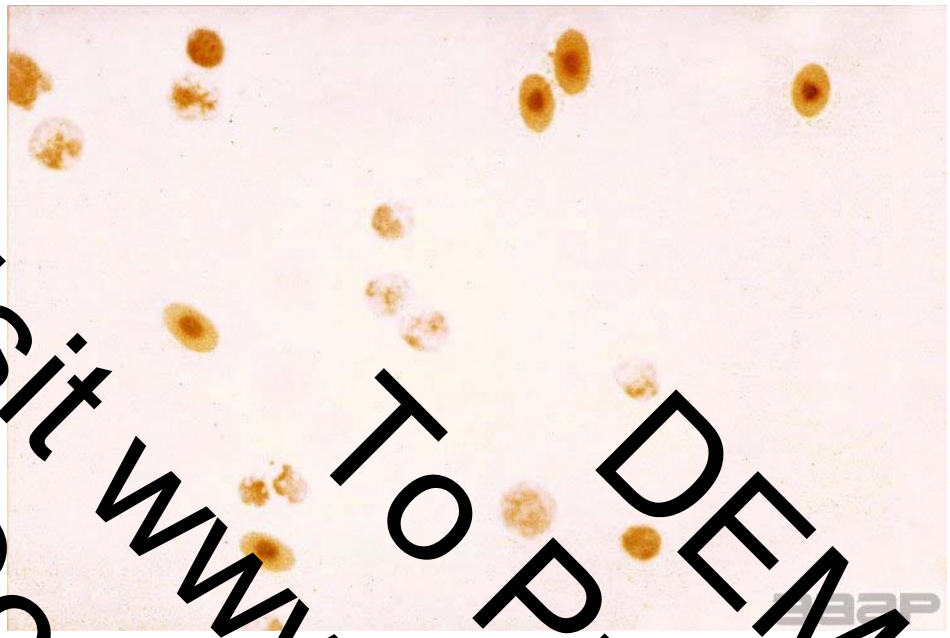

SLIDE 1.11 Smears of the joint fluid (synovia) stained with May-Grunwald Giemsa stain reveal many heterophils, lymphocytes, monocytes, and macrophages. Normal synovia may contain an occasional monocyte or a sloughed synovial cell. Care should be taken not to squash the cells when making the smear to prevent the appearance of bizarre cells that are difficult to identify. Blood should be avoided in taking the smear. Heterophils are not seen in normal synovium.

Click here to access (1.11.jpg) jpg file for printing and copying

DEMO
To Purchase
Visit www.aaap.info/slides
Copyright by AAAP

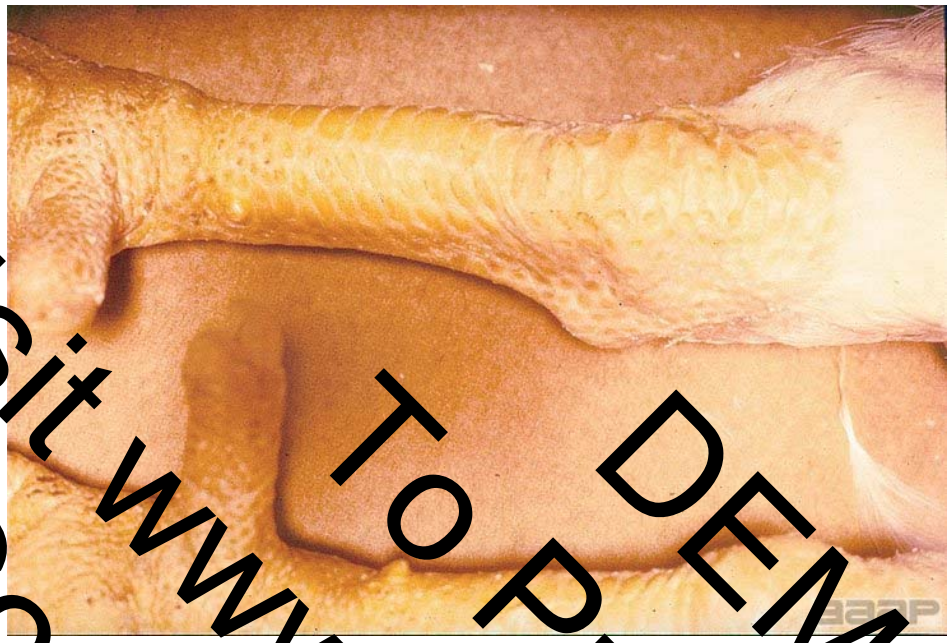

SLIDE 12. Tarsal bursitis may or may not be associated with viral arthritis. Tarsal bursitis occurs in nearly 100% of battery-reared birds in the absence of viral arthritis. The upper leg shows tarsal bursitis plus enlarged digital flexor tendons. The lower leg shows enlarged digital flexor tendons with no tarsal bursitis. Breast blisters have been associated more with management conditions than with viral arthritis, as has tarsal bursitis.

Click here to access (1.12.jpg) jpg file for printing and copying

DEMO
To Purchase
Visit www.aaap.info/slides
Copyright by AAAP

SLIDE 13. Starting at about 42 days post-infection, erosions appear in the cartilage of the posterior and distal tibia.

Click here to access (1.13.jpg) jpg file for printing and copying

DEMO
To Purchase
Visit www.aaap.info/slides
Copyright by AAAP

SLIDE 14: Normal tendon sheaths from the digital flexor tendons of the shank (H & E X 30)

Click here to access (1.14.jpg) jpg file for printing and copying

DEMO
To Purchase
Visit www.aaap.info/slides
Copyright by AAAP

SLIDE 15. Infected tendon sheaths from the digital flexor tendons of the shank of a chicken with viral arthritis (6 weeks of age, 3 weeks post-inoculation), showing a thickened synovium due to hyperplasia of synovial cells and connective tissue with extensive accumulation of lymphocytes, plasma cells, and heterophils. The accumulation of these cell types is present in the synovial cavity (H & E X 30). (Contributed by Dr. K. M. Kerr, Department of Pathology, Ohio state University, Columbus). Chickens at this stage may recover or progress to the chronic stage, as seen in 21.
See also slides 16, 17, and 18.

Click here to access (1.15.jpg) jpg file for printing and copying

DEMO
To Purchase
Visit www.aaap.info/slides
Copyright by AAAP

SLIDE 16. Infected tendon sheaths from the digital flexor tendons of the shank of a chicken with viral arthritis (6 weeks of age, 3 weeks post-inoculation), showing a thickened synovium due to hyperplasia of synovial cells and connective tissue with extensive accumulation of lymphocytes, plasma cells, and heterophils. The accumulation of these cell types is present in the synovial cavity (H & E X 30). (Contributed by Dr. K. M. Kerr, Department of Pathology, Ohio state University, Columbus). Chickens at this stage may recover or progress to the chronic stage, as seen in 21.
See also slides 15, 17, and 18.

Click here to access (1.16.jpg) jpg file for printing and copying

DEMO
To Purchase
Visit www.aaap.info/slides
Copyright by AAAP

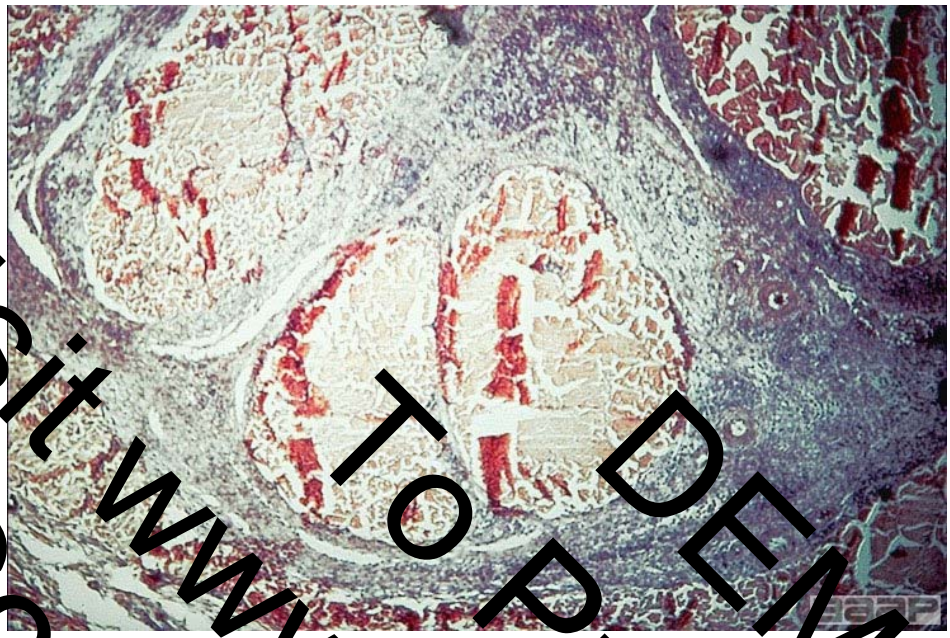

SLIDE 17. Infected tendon sheaths from the digital flexor tendons of the shank of chicken with viral arthritis (6 weeks of age, 3 weeks post-inoculation), showing thickened synovium due to hyperplasia of synovial cells and connective tissue with extensive accumulation of lymphocytes, plasma cells, and heterophils. The accumulation of these cell types is present in the synovial cavity (H & E X 30). (Contributed by Dr. K. M. Kerr, Department of Pathology, Ohio state University, Columbus). Chickens at this stage may recover or progress to the chronic stage, as seen in 21.
See also slides 15, 16, and 18.

Click here to access (1.17.jpg) jpg file for printing and copying

Visit www.aaap.info/slides
DEMO
To Purchase
Copyright by AAAP

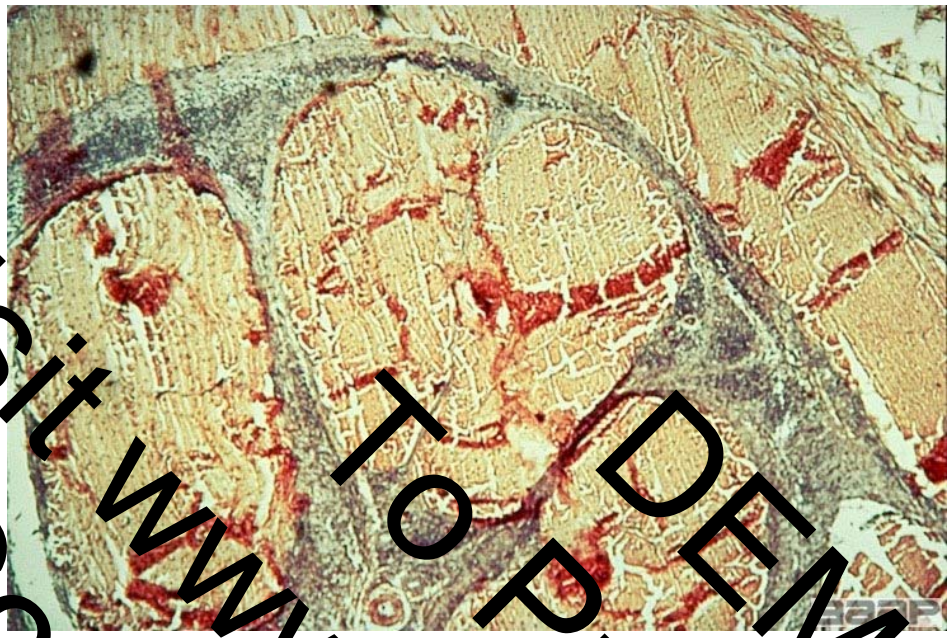

SLIDE 18. Infected tendon sheaths from the digital flexor tendons of the shank of chicken with viral arthritis (6 weeks of age, 3 weeks post-inoculation), showing thickened synovium due to hyperplasia of synovial cells and connective tissue with extensive accumulation of lymphocytes, plasma cells, and heterophils. The accumulation of these cell types is present in the synovial cavity (H & E X 30). (Contributed by Dr. K. M. Kerr, Department of Pathology, Ohio state University, Columbus). Chickens at this stage may recover or progress to the chronic stage, as seen in 21.
See also slides 15, 16, and 17.

Click here to access (1.18.jpg) jpg file for printing and copying

Visit www.aaap.info/slides
DEMO
To Purchase
Copyright by AAAP

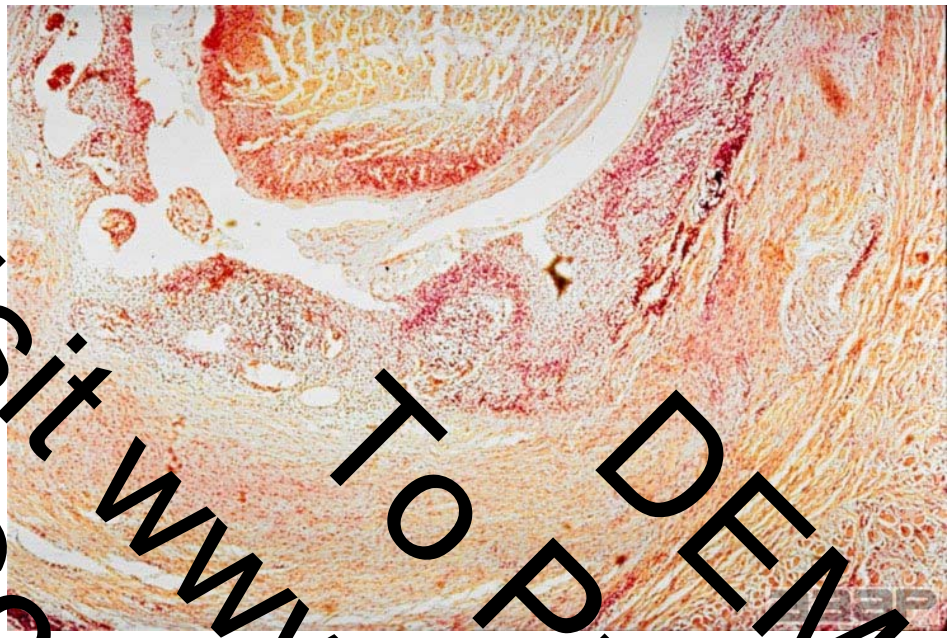

SLIDE 19: Chronic viral arthritis with fibrosis in the digital flexor tendon.

Click here to access (1.19.jpg) jpg file for printing and copying

DEMO
To Purchase
Visit www.aaap.info/slides
Copyright by AAAP

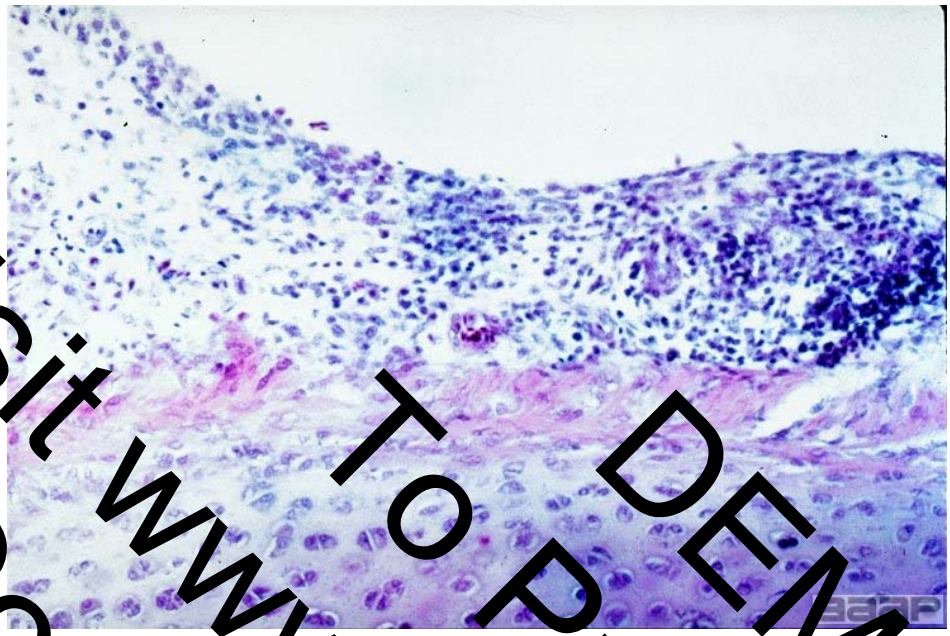

SLIDE 20: Pannus formation in viral arthritis. (Contributed by Dr. Van den Heide, Dept. of Pathobiology, Univ. of Connecticut, Storrs).

Click here to access (1.20.jpg) jpg file for printing and copying

DEMO
To Purchase
Visit www.aaap.info/slides
Copyright by AAAP

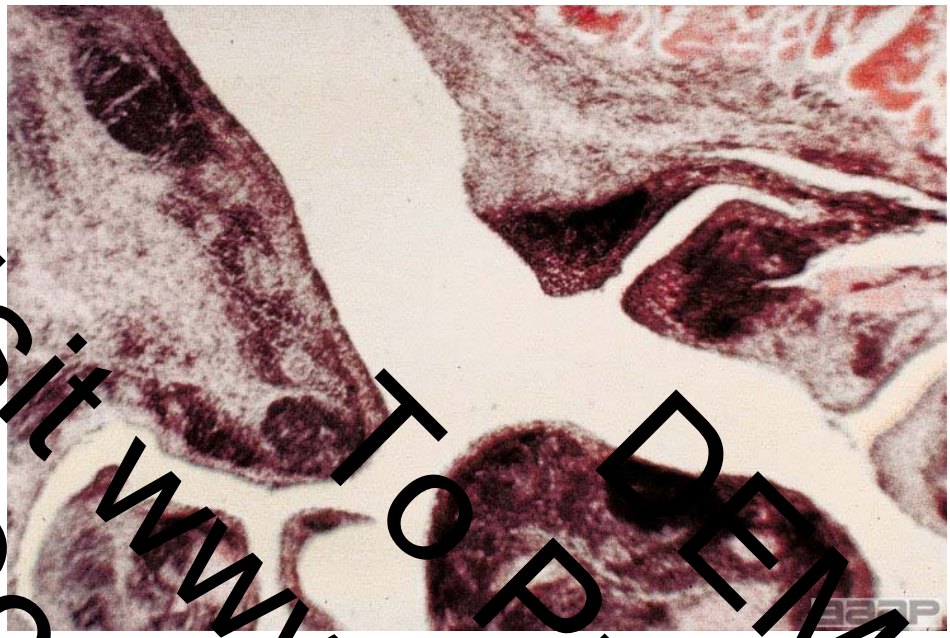

SLIDE 21: Taken from same area as 15, showing chronic changes in the synovium and development of fibrous tissue and lymphoid follicles composed of proliferating lymphocytes (H & E x 50)

Click here to access (1.21.jpg) jpg file for printing and copying

DEMO
To Purchase
Visit www.aaap.info/slides
Copyright by AAAP

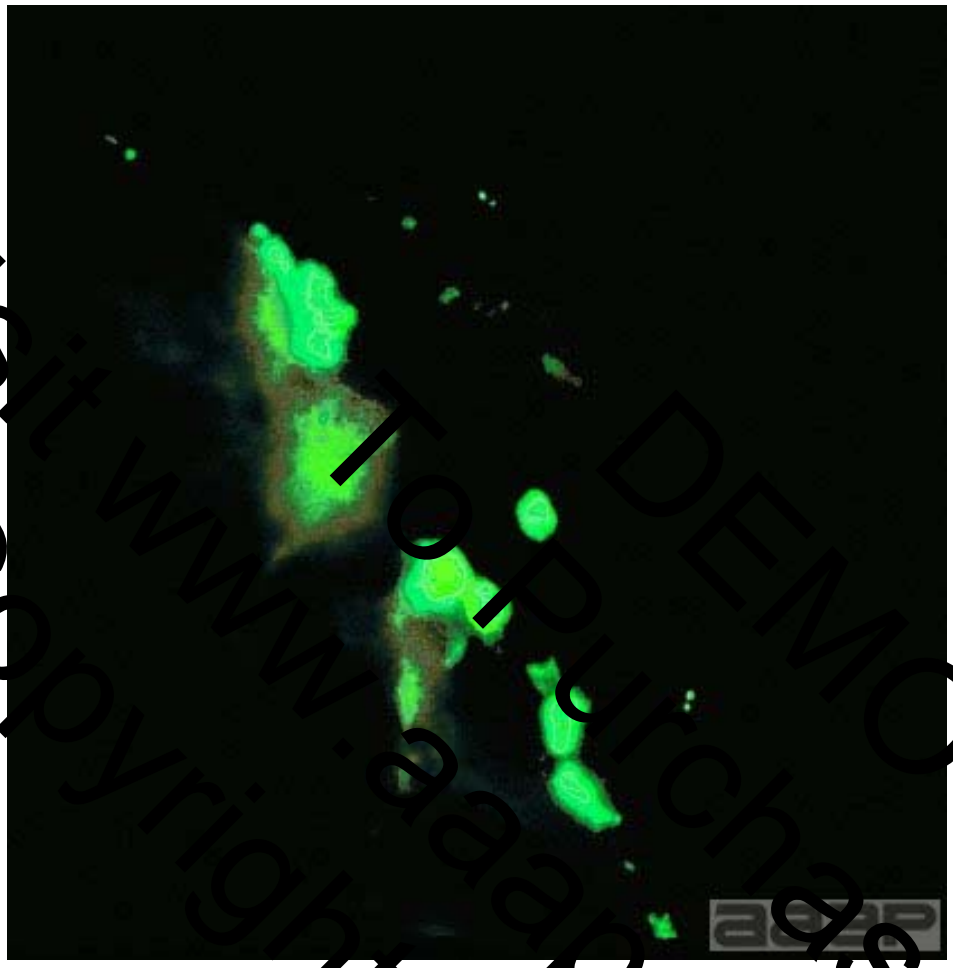

SLIDE 22. Fluorescent antibody staining of the synovium demonstrating the virus in the synovial cells 3 weeks post-inoculation (x 400).

Click here to access (1.22.jpg) jpg file for printing and copying

Visit www.aaap.info/slides
Copyright by AAAP
To Purchase
DEMO



SLIDE 23: The virus particles are arranged in a crystalline array (V) in the cytoplasm of a mesenchymal cell (4 days after inoculation of chorioallantoic membrane) of a chicken embryo with viral arthritis WVU 2937 (x 50,000). (Contributed by Elizabeth Walker, Dept. of Anatomy, West Virginia University Medical School).

Click here to access (1.23.jpg) jpg file for printing and copying

Visit www.aaap.info/slides To Purchase DEMO Copyright by AAAP

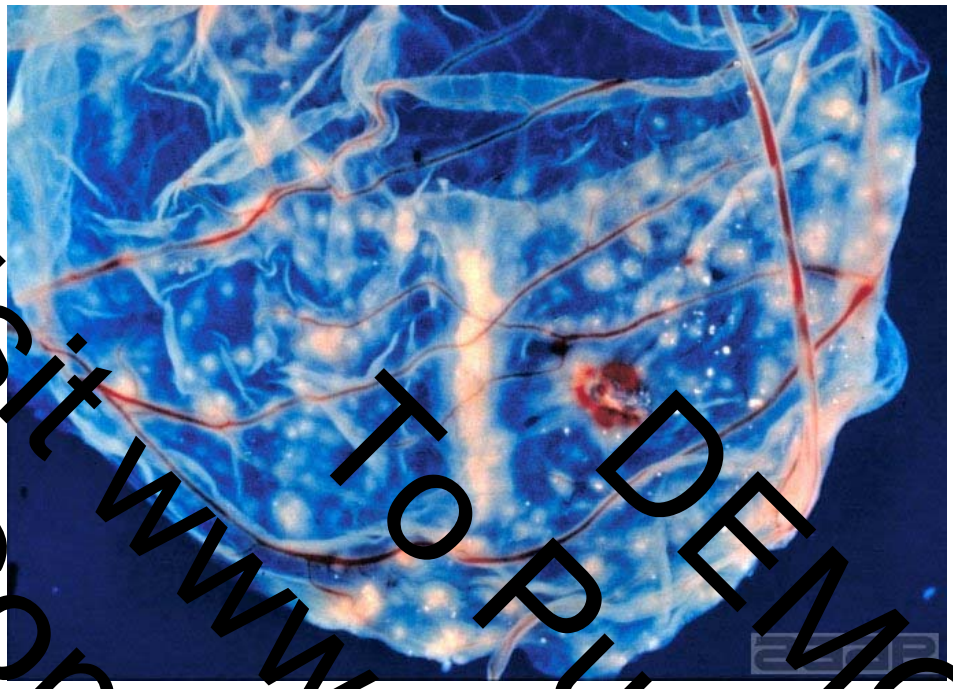

SLIDE 24. Inoculation of 10-day-old embryonating chicken eggs on the dropped chorioallantoic membrane (CAM) results in the development of whitish plaques in 3 to 5 days post-inoculation.

Click here to access (1.24.jpg) jpg file for printing and copying

DEMO
To Purchase
Visit www.aaap.info/slides
Copyright by AAAP

SLIDE 25. Whitish plaques on the dropped chorioallantoic membrane (CAM) from a 16-day-old embryo, 6 days post-inoculation.

Click here to access (1.25.jpg) jpg file for printing and copying

DEMO
To Purchase
Visit www.aaap.info/slides
Copyright by AAAP

SLIDE 26. Inoculation of 5- to 7-day-old embryonating chicken eggs by the yolk sac route or on the dropped CAM results in death of the embryo in 3-5 days. This markedly hemorrhagic 12-day-old embryo died 5 days post-inoculation via the yolk sac route.

Click here to access (1.26.jpg) jpg file for printing and copying

Visit www.aaap.info/slides
To Purchase
DEMO
Copyright by AAAP

SLIDE 27. Embryos inoculated with lower concentrations of the virus survive until the 16th to 20th day. The embryo shown here is 17 days old, 10 days post-inoculation via the yolk sac route. One section of the liver is cut away to reveal the spleen. The embryo is slightly dwarfed. The heart, liver and spleen are enlarged and contain necrotic foci.

Click here to access (1.27.jpg) jpg file for printing and copying

DEMO
To Purchase
Visit www.aaap.info/slides
Copyright by AAAP

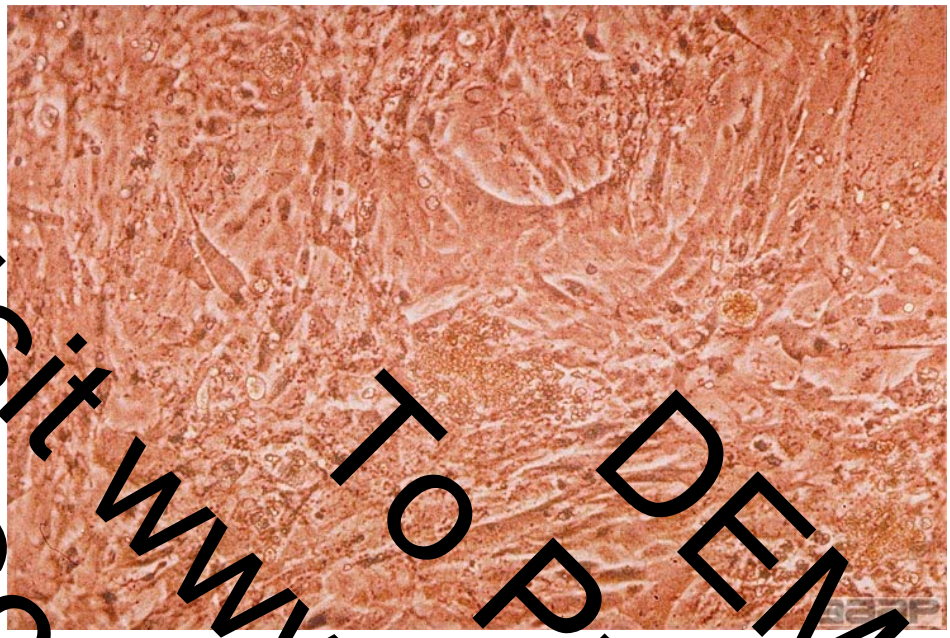

SLIDE 28: Growth of the virus on cell culture: the most striking effect is the formation of syncytia by the epithelial cells in chick kidney culture, often as early as 18-24 hours post-infection (phase contrast X 50). (Contributed by Dr. Stanley Kleven, University of Georgia, Athens).
See also slides 29 and 30.

Click here to access (1.28.jpg) jpg file for printing and copying

DEMO
To Purchase
Visit www.aaap.info/slides
Copyright by AAAP

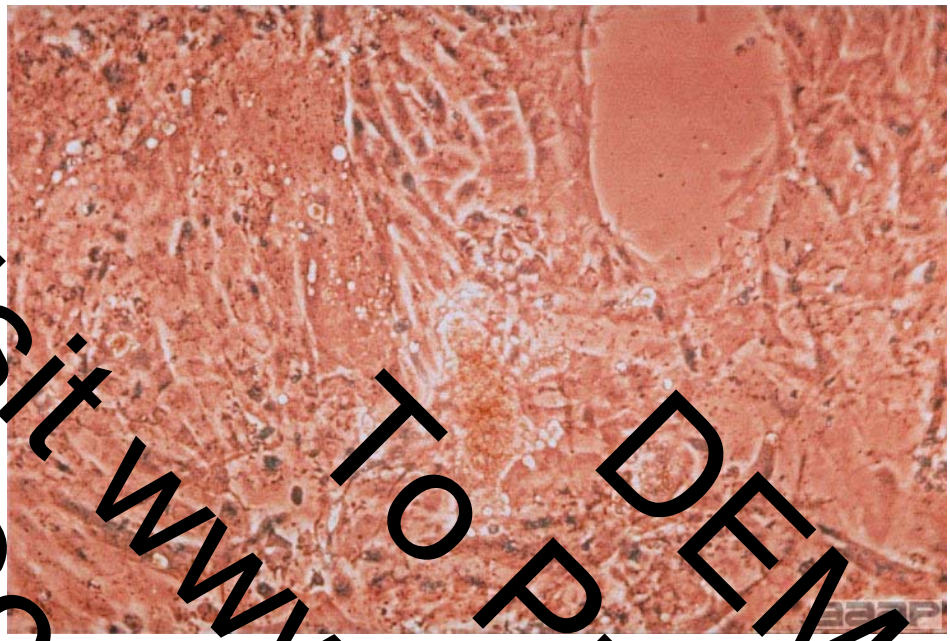

SLIDE 29: Growth of the virus on cell culture: The syncytia degenerate and float free, leaving holes in the monolayers (phase contrast X 50). (Contributed by Dr. Stanley Kleven, University of Georgia, Athens.)
See also slides 28 and 30.

Click here to access (1.29.jpg).jpg file for printing and copying

DEMO
To Purchase
Visit www.aaap.info/slides
Copyright by AAAP

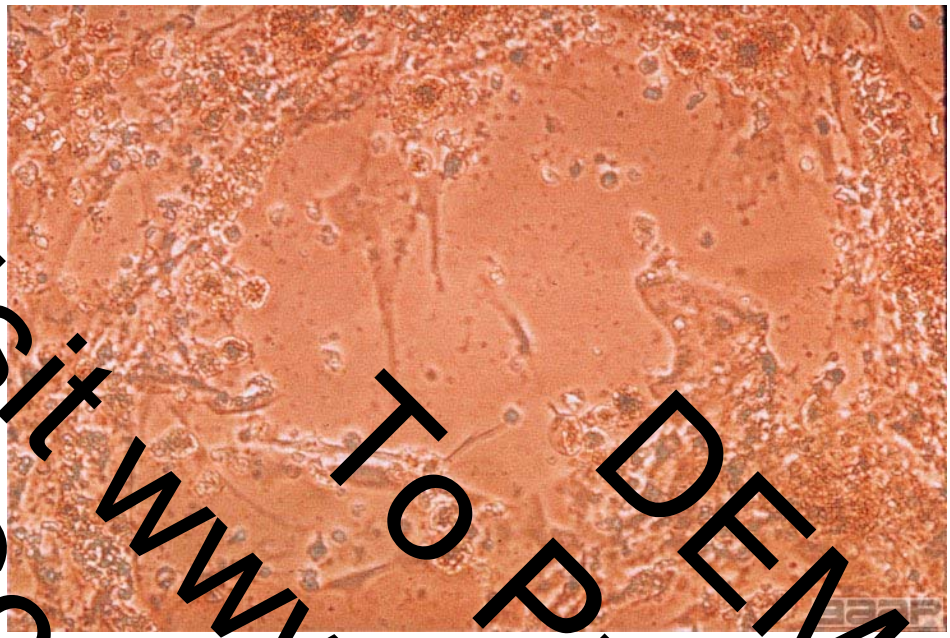

SLIDE 30: Growth of the virus on cell culture: Syncytia are not formed in cultures of fibroblasts, but the cells round up and degenerate 72 hours post-infection (phase contrast X 50). (Contributed by Dr. Stanley Kronen, University of Georgia, Athens).
See also slides 28 and 29.

Click here to access (1.30.jpg).jpg file for printing and copying

DEMO
To Purchase
Visit www.aaap.info/slides
Copyright by AAAP

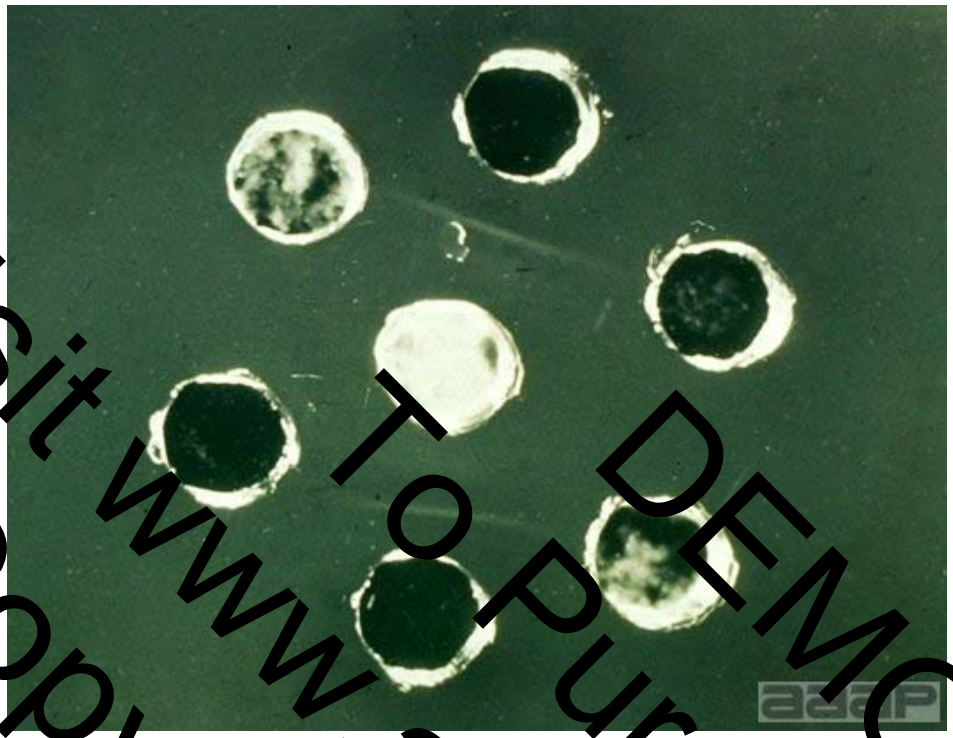

SLIDE 31. The agar gel precipitin (AGP) test is a rapid method used for the diagnosis of viral arthritis. The center well contains virus prepared from ground CAM. The top and bottom wells contain positive serum. The other 4 wells contain negative serum and normal ground CAM. Note white precipitin line between the positive serum and virus. The AGP test is used to detect antibodies to reoviruses. For specific serotype identification of the virus, neutralization or complement fixation test should be used.

Click here to access (1.31.jpg) jpg file for printing and copying

DEMO
To Purchase
Visit www.aaap.info/slides
Copyright by AAAP