

# INFECTIOUS CORYZA

Slide study set #10

*Prepared by:*

**R. B. RIMLER**

National Animal Disease Center

P.O. Box 70

Ames, Iowa 50010

*and*

**R. B. DAVIS**

Poultry Diseases Research Center

University Of Georgia

Athens, Georgia 30602

**This slide study set was created in 1983; some information may be outdated.**

COPYRIGHT 1983

AMERICAN ASSOCIATION OF AVIAN PATHOLOGISTS, INC.



AAAP BUSINESS OFFICE  
NEW BOLTON CENTER  
382 WEST STREET RD.  
KENNETT SQUARE, PA 19348

*CD version produced in 2001 with the assistance of the AAAP Continuing Education and Electronic Information Committees*

## INFECTIOUS CORYZA

By: R.B. RIMLER and R.B. DAVIS

---

Infectious coryza of chickens is an acute respiratory disease caused by *Haemophilus paragallinarum*. The disease occurs in poultry raising areas throughout the world. Although infectious coryza can be experimentally produced in quail with *H. paragallinarum* (1), naturally occurring disease is common only to chickens.

The disease in chickens occurs in both uncomplicated and complicated forms. The uncomplicated form (produced by *H. paragallinarum* only) results in rapid onset of clinical signs, usually 1 to 3 days after exposure. These signs persist from 7 to 14 days on the average. The complicated disease is usually more severe and may take a chronic course, depending on the complicating agent: *Escherichia coli*, *Pasteurella* mycoplasmas, fowl pox virus, infectious bronchitis virus, and laryngotracheitis virus may be complicating agents. Evidence suggests that the chronic complicated coryza produced by *H. paragallinarum* and *Mycoplasma gallisepticum* or *M. synoviae* is the prevalent form of the disease in most areas outside of the United States.

---

**The Uncomplicated Disease.** The uncomplicated disease occurs in both growing chickens and layers, particularly where multiple-age management practices are used. Economic loss is due to increased numbers of culls and lowered egg production. Egg production may decrease 10-40%.

All ages of chicken are susceptible to *H. paragallinarum* infection. The disease is more severe in older chickens, especially roosters. Chronically infected or healthy carrier birds are the main source of infection. The causative organism is transmitted by aerosol or through contaminated drinking water. Drinking water is considered the principal means of transmission.

**Clinical signs and gross lesions.** Uncomplicated infectious coryza is manifested as an acute catarrhal inflammation of the mucous membranes of the nasal passages and sinuses. Conjunctivitis and edema of the face and wattles occur frequently (2). Edema may occur on one or both sides of the face and may be so extensive that vision is obscured. Facial edema can be a transient sign lasting only 3 to 4 days and may not occur in chicks 1 to 3 weeks of age. Wattle edema is observed more often in older males and may become chronic.

The chief sign is a serous to mucoïd exudate from one or both nostrils. This may be the only sign in many chickens. The nasal exudate from chickens with recent infection is usually clear; exudate may become cloudy as infection persists. Accumulation of feed on the beak around the nares is a clue to nasal discharge.

Depression may occur and result in a decrease in feed and water consumption.

Involvement of the lower respiratory tract sometimes occurs, causing rales and breathing difficulties. Chickens having lower respiratory-tract infection may breathe through the mouth and produce "gurgling" noises.

Airsacculitis may occur in uncomplicated infectious coryza. Occurrence is probably dependent on the strain of *H. paragallinarum*. Airsacculitis levels of 65% have been reported in uncomplicated infection (3).

**Histopathology.** Lesions are most often observed in the upper respiratory tract. Affected areas of epithelium in the nasal cavity, infraorbital sinuses, and trachea undergo

## REFERENCES

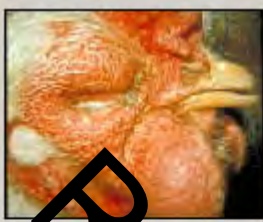1. Cundy, K.R. Susceptibility of Japanese quail (*Coturnix coturnix japonica*) to experimental infection with *Haemophilus gallinarum*. *Avian Dis.* 9: 272-284. 1965.
2. Yamamoto, P. Infectious coryza, In: *Diseases of Poultry*, 7<sup>th</sup> ed., M.S. Hofstad, B.W. Calnek, C.F. Helmboldt, W.M. Reid, and H.W. Yoder, Jr., eds. pp. 225-232. Iowa State University Press. 1978.
3. Page, L.A. *Haemophilus* infections in chickens. I. Characteristics of *Haemophilus* isolates recovered from diseased chickens. *Am. J. Vet. Res.* 23: 85-95. 1962.
4. Rimler, R.B., and R.B. Davis. Infectious coryza: In vivo growth of *Haemophilus gallinarum* as a determinant for cross-protection. *Am. J. Vet. Res.* 38: 1591-1593. 1977.

## ACKNOWLEDGMENTS

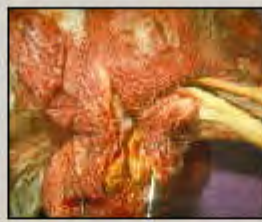Appreciations extended to Dr. K. R. Enoades for his contribution to the histopathology section.



10.01.jpg



10.02.jpg



10.03.jpg



10.04.jpg



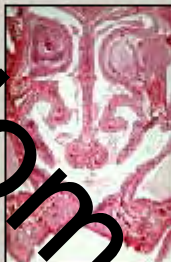10.05.jpg



10.06.jpg



10.07.jpg



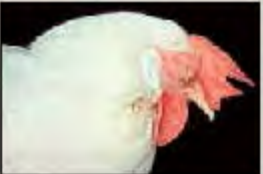10.08.jpg



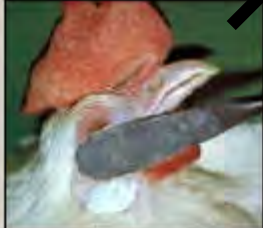10.09.jpg



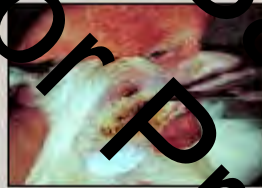10.10.jpg



10.11.jpg



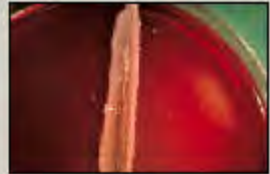
10.12.jpg



10.13.jpg




10.14.jpg



10.15.jpg



10.16.jpg



10.17.jpg



10.18.jpg

Random Sample Pages for Preview